

# Donor Site Morbidity in Phalloplasty Reconstructions: Outcomes of the Radial Forearm Free Flap

❖ **Phalloplasty**  
Surgical procedure where a penis is created

❖ **Who needs phalloplasty?**  
Female-to-male (FTM) gender confirmation, ambiguous genitalia, aphalia, epispadias, hypospadias, micropenis, trauma to the penis

❖ **Procedure:**  
Creation of the penis, lengthening the urethra, creating glans, creation of the scrotum, (removal of the vagina), placing erectile and testicular implants

❖ **Donor sites:**

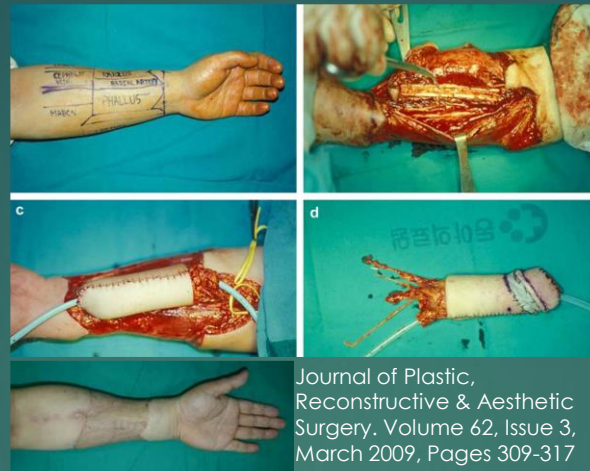- Radial forearm free flaps: excellent cosmetic results and better sensation
- Anterolateral thigh free flaps: you more penis length options. Scars on the thigh easier to hide
- Latissimus dorsi flaps: less scarring. Best potential for an erection without a device.
- Factors that indicate which donor site is used include patient's health, fat distribution, nerve functionality, blood flow, patient goals, desired surgical outcomes

❖ Radial forearm free flaps : large donor site may increase the potential for donor site morbidity, such as nerve injury, delayed wound healing, and decreased hand strength.

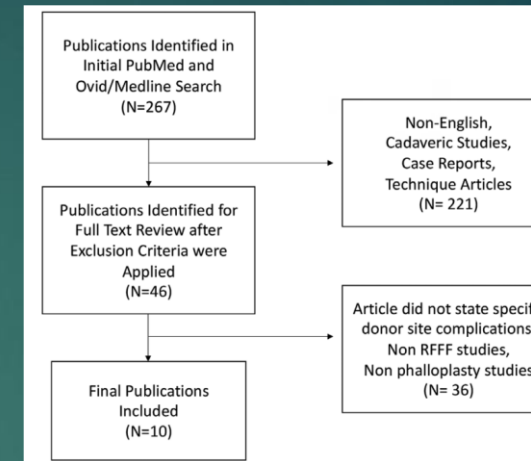
❖ **Systemic review to assess the donor site morbidity associated with RFFF phalloplasty (RFFFP)**

## ❖ Methods

- Search terms: phalloplasty, radial, forearm, donor site, complication, and flap
- Two authors performed independent reviews of the literature within the PubMed and Ovid/Medline databases



Journal of Plastic, Reconstructive & Aesthetic Surgery. Volume 62, Issue 3, March 2009, Pages 309-317



## ❖ Results/ conclusions

- The most common indication for surgery: gender affirmation 77.7% (n= 730)
- Other indications: trauma/oncologic injury (n = 32), bladder or cloacal exstrophy (n = 26), and agenesis/aplasia (n = 8)
- RFFF sizes 4×17 cm2- 16×16 cm2, average 167cm2
- Overall complication rate: 7.9% (74/940)
- Donor site complications: infection, hematoma, dehiscence, neuroma formation, nerve compression/ compartment syndrome, skin graft failure, decreased, strength/sensation, lymphedema/swelling, and contracture
- Most commonly reported complications: skin graft failure (8/10), decreased strength/sensation (6/10)
- In comparison with other reconstructive applications of the RFFF, phalloplasty does not seem to increase the comparative rate of complications, despite utilizing much larger flaps
- Surgeons and patients should thoroughly discuss the flap options for genital reconstruction and compare the phallus outcomes with the donor site morbidity to determine the appropriate surgical plan for the patient

**Table 1. Included Study Cohort Average Age, Follow-Up, Indication for Surgery**

Author	Year	Patients	Age	Follow-Up	Gender Confirmation	Trauma/ Oncologic/ Medical	Bladder/ Cloacal Exstrophy	Agenesis/ Aplasia
Selvaggi et al <sup>9</sup>	2006	125	—	43 (6–108)	125	—	—	—
Monstrey et al <sup>10</sup>	2009	287	—	—	280	3	—	4
Garaffa et al <sup>11</sup>	2009	15	43.6 (39–54)	85.2 (24–216)	—	15	—	—
Garaffa et al <sup>12</sup>	2010	115	34.9 (20–55)	—	—	—	—	—
Garaffa et al <sup>12</sup>	2010	27	40.4 (30–55)	9.2 (1–32)	—	—	—	—
Doornaert et al <sup>13</sup>	2011	316	—	—	306	4	—	4
Song et al <sup>14</sup>	2011	19	—	(12–120)	19	—	—	—
Massanyi et al <sup>15</sup>	2013	10	19	14 (2–52)	—	—	10	—
Garaffa et al <sup>16</sup>	2014	16	23.619–29	20.52–38	—	—	16	—
Falcone et al <sup>17</sup>	2016	10	36 (27–52)	—	—	10	—	—

**Table 2. Donor Site Complications by Article**

Author	Year	Patients	Infection	Hematoma	Dehiscence	Neuroma	Nerve Compression/ Compartment Syndrome	Skin Graft Failure	Decreased Strength/ Sensation	Lymphedema/ Swelling	Contracture
Selvaggi et al <sup>9</sup>	2006	125	—	1 (0.8%)	—	—	—	11 (8.8%)	1 (0.8%)	7 (5.6%)	—
Monstrey et al <sup>10</sup>	2009	287	—	—	—	—	—	2 (0.7%)	—	—	—
Garaffa et al <sup>11</sup>	2009	15	—	—	—	—	—	2 (13.3%)	2 (13.3%)	1 (6.7%)	2 (13.3%)
Garaffa et al <sup>12</sup>	2010	115	—	—	—	—	1 (0.9%)	7 (6.1%)	12 (10.4%)	2 (1.7%)	—
Garaffa et al <sup>12</sup>	2010	27	—	—	—	—	—	3 (11.1%)	0 (0%)	—	—
Doornaert et al <sup>13</sup>	2011	316	—	—	—	—	—	13 (4.1%)	—	—	—
Song et al <sup>14</sup>	2011	19	3 (15.8%)	—	—	—	—	—	—	—	—
Massanyi et al <sup>15</sup>	2013	10	—	—	—	1 (1%)	—	—	—	—	—
Garaffa et al <sup>16</sup>	2014	16	—	—	—	—	—	3 (18.8%)	0 (0%)	—	0 (0%)
Falcone et al <sup>17</sup>	2016	10	—	—	0 (0%)	—	0 (0%)	0 (0%)	0 (0%)	—	—

Donor Site Morbidity in Phalloplasty Reconstructions: Outcomes of the Radial Forearm Free Flap. Plast Reconstr Surg Glob Open. 2019 Sep 23;7(9):e2442. Alexandra Kovar , Susie Choi , Matthew L Iorio