

Resuscitative Endovascular Balloon Occlusion of the Aorta as a Bridge to Organ Donation After Blunt Trauma

Joshua J. Sumislawski, MD; Dylan P. Foley, MS;
Ernest E. Moore, MD; Hunter B. Moore, MD, PhD
Journal of Endovascular Resuscitation and Trauma Management (JEVTM)

ABSTRACT

Solid organ transplantation is limited worldwide by a shortage of donor organs. Trauma patients with unsurvivable injuries comprise a large portion of potential organ donors, but many of them die from cardiovascular collapse before donation can be pursued. We report the use of resuscitative endovascular balloon occlusion of the aorta (REBOA) to stabilize a deteriorating blunt trauma patient who was ultimately able to donate multiple organs and tissues. Survival to organ donation is a tangible and beneficial outcome of REBOA.

INTRODUCTION

- ❖ Number of organs transplanted increases annually
- ❖ Available organs < prospective recipients
- ❖ 106,782 candidates waiting for transplant (August 2021)¹
- ❖ Deceased patients comprise the majority of donor pool¹
- ❖ 11,870 cadaveric donors provided 32,322 transplanted organs, representing 81% of transplants (2019)¹
- ❖ Donor pool cause of death top two¹
 - 1) Cerebrovascular accident
 - 2) Traumatic brain injury
- ❖ Additional efforts to expand donor pool¹²⁻²⁰
 - REBOA
 - Extended donor criteria
 - Longer cold times
 - Antivirals
 - Resuscitative thoracotomy
 - uDCD

THE CASE

53F cardiac arrest following high energy motor vehicle collision

Prehospital Course

- ❖ Agonal breathing on scene
- ❖ CPR for 17 minutes
- ❖ Fixed pupils
- ❖ Lip laceration

THE CASE CONTINUED

Emergency Department Course

- ❖ Per institutional protocol not a candidate for resuscitative thoracotomy⁵⁻⁶
- ❖ CPR paused, faint carotid pulse found
- ❖ EFAST negative X2
- ❖ 7-French ER-REBOA placed 45 cm at skin|13 mL saline diluted contrast to inflate balloon
- ❖ BP increased to 117/60 mm Hg
- ❖ Time, position, balloon volume recorded (Figure 1)
- ❖ Simultaneous intubation, intravenous access, and pelvic stabilization with a sheet
- ❖ Chest XR confirmed placement in zone 1 of the aorta and demonstrated no major thoracic injuries (Figure 2)
- ❖ CT pan scan performed with partially inflated balloon (11 mL)
- ❖ 26 minutes after inflation patient had received three units packed red cells and two units of plasma
- ❖ 43 minutes balloon completely deflated with BP of 110/83 mm Hg
- ❖ Notable labs and imaging
 - Hemoglobin 11.4 g/dL | Base Deficit -22.0 mmol/L
 - CT Pan Scan: bilateral cerebral subarachnoid hemorrhages, left frontal lobe intraparenchymal hemorrhage, intraventricular hemorrhage, atlanto-occipital dissociation, multifocal C1 fractures, bilateral rib fractures

Intensive Care Unit Course

- ❖ Norepinephrine infusion to maintain systolic BP >100 mm Hg
- ❖ No brainstem reflexes
- ❖ MRI grade 1 diffuse axonal injury and diffuse hypoxic ischemic injury
- ❖ Discussion with family and authorization for organ procurement following circulatory death
- ❖ Liver and two kidneys procured and donated to three recipients on fifth hospital day
 - Kidney biopsy at procurement negative for acute tubular necrosis

DISCUSSION

- ❖ Multiorgan failure and cardiovascular collapse result from hemodynamic, metabolic, and endocrine derangements following TBI⁷⁻¹⁰
- ❖ 25% of possible organ donors lost to hemodynamic instability²⁻⁴
- ❖ In this case, the aorta was completely occluded for only 10 minutes, avoiding prolonged ischemia to abdominal viscera
- ❖ Progress is being made, but there is still a discrepancy between donor organs and prospective recipients
- ❖ The organ donation process is ethically complex
- ❖ Alternatives must be explored in attempt to expand donor pool while conforming to societal expectations
- ❖ REBOA can provide precious time for family and care teams to make difficult decisions
- ❖ REBOA is becoming more common but is still controversial
- ❖ Future work should explore organ donation outcomes of REBOA

REFERENCES

1. Organ Procurement and Transplantation Network. National Data. Available at: <https://optn.transplant.hrsa.gov/data/view-data-reports/national-data/>. Accessed August 24, 2021.
2. Nygard CE, Townsend RN, Diamond DL. Organ donor management and organ outcome: a 6-year review from a Level I trauma center. *J Trauma*. 1990;30(6):728-32.
3. Mackersie RC, Bronshter OL, Shaddock SR. Organ procurement in patients with fatal head injuries. The fate of the potential donor. *Ann Surg*. 1991;213(2):143-50.
4. Kennedy AP Jr, West JC, Kelley SE, Brotman S. Utilization of trauma-related deaths for organ and tissue harvesting. *J Trauma*. 1992;33(4):516-20.
5. Burlew CC, Moore EE, Moore FA, et al. Western Trauma Association critical decisions in trauma: resuscitative thoracotomy. *J Trauma Acute Care Surg*. 2012;73(6):1359-63.
6. Moore HB, Moore EE, Burlew CC, et al. Establishing benchmarks for resuscitation of traumatic circulatory arrest: success-to-rescue and survival among 1,708 patients. *J Am Coll Surg*. 2016;223(1):42-50.
7. Power BM, Van Heerden PV. The physiological changes associated with brain death—current concepts and implications for treatment of the brain dead organ donor. *Anaesth Intensive Care*. 1995;23(1):26-36.
8. Manley G, Knudson MM, Morabito D, Damron S, Erickson V, Pitts L. Hypotension, hypoxia, and head injury: frequency, duration, and consequences. *Arch Surg*. 2001;136(10):1118-23.
9. Salim A, Martin M, Brown C, Belzberg H, Rhee P, Demetriades D. Complications of brain death: frequency and impact on organ retrieval. *Am Surg*. 2006;72(5):377-81.
10. Essien EO, Fioretti K, Scalea TM, Stein DM. Physiologic features of brain death. *Am Surg*. 2017;83(8):850-4.
11. Foley DP. Impact of donor warm ischemia time on outcomes after donation after cardiac death liver transplantation. *Liver Transpl*. 2014;20(5):509-11.
12. Abouna GM. Organ shortage crisis: problems and possible solutions. *Transplant Proc*. 2008;40(1):34-8.
13. Boyarsky BJ, Strauss AT, Seger DL. Transplanting organs from donors with HIV or hepatitis C: the viral frontier. *World J Surg*. 2021;45(12):3503-10.
14. Choudhury RA, Prins K, Dor Y, Moore HB, Yaffe H, Nydam TL. Uncontrolled donation after circulatory death improves access to kidney transplantation: a decision analysis. *Clin Transplant*. 2020;34(7):e13868.
15. Circelli A, Brogi E, Gamberini E, et al. Trauma and donation after circulatory death: a case series from a major trauma center. *J Int Med Res*. 2021;49(2):3000605211000519.
16. Coll E, Miñambres E, Sánchez-Fructuoso A, Fondevila C, Campo-Cañaveras de la Cruz JL, Dominguez-Gil B. Uncontrolled donation after circulatory death: a unique opportunity. *Transplantation*. 2020;104(8):1542-52.
17. Brenner M, Inaba K, Aioli A, et al. Resuscitative endovascular balloon occlusion of the aorta and resuscitative thoracotomy in select patients with hemorrhagic shock: early results from the American Association for the Surgery of Trauma's Aortic Occlusion in Resuscitation for Trauma and Acute Care Surgery Registry. *J Am Coll Surg*. 2018;226(5):730-40.
18. Hadley JB, Coleman JR, Moore EE, et al. Strategies for successful implementation of resuscitative endovascular balloon occlusion of the aorta (REBOA) in an urban Level I trauma center. *J Trauma Acute Care Surg*. 2021;91(2):295-301.
19. Schnirger B, Inaba K, Branco BC, et al. Organ donation: an important outcome after resuscitative thoracotomy. *J Am Coll Surg*. 2010;211(4):450-5.
20. Magliocco JP, Magee JC, Rowe SA, et al. Extracorporeal support for organ donation after cardiac death effectively expands the donor pool. *J Trauma*. 2005;58(6):1095-102.

FIGURES

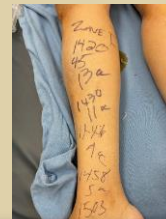

Figure 1: Time, catheter position, and balloon volume recorded on patients right lower extremity

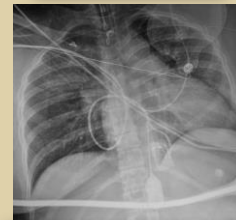


Figure 2: Chest XR after REBOA placement

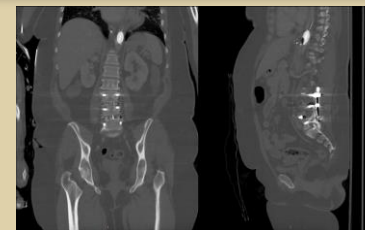


Figure 3: Coronal (left) and sagittal (right) views of the patient's CT scan demonstrating zone 1 REBOA placement