Differences in Hip Alpha Angles on Different Imaging Modalities

University of Colorado
Anschutz Medical Campus

Colton Lynn

Stephanie Mayer, Whitney L. Hovater, Alex Lencioni, Winthrop Lockwood

University of Colorado Anschutz

Background

- Identify differences in alpha angles on plain radiographs, MRIs, and CTs of patients diagnosed with abnormal hip pathologies.
- Determine which modality is the most effective at predicting patient outcomes.

Methods

- Retrospective review of 60 (n=93 hips) patients diagnosed with:
  - Pelvic apophyseal injuries
  - Slipped capital femoral epiphysis (SCFE)
  - Hip dysplasia
  - Legg-Calvé-Perthes disease
  - Femoroacetabular impingement (FAI)
- Imaging performed prior to intervention:
  - Plain radiograph
  - MRI
  - CT
- We compared the alpha angle of the affected hips using a one-way ANOVA and defined statistical significance as $p<0.05$.

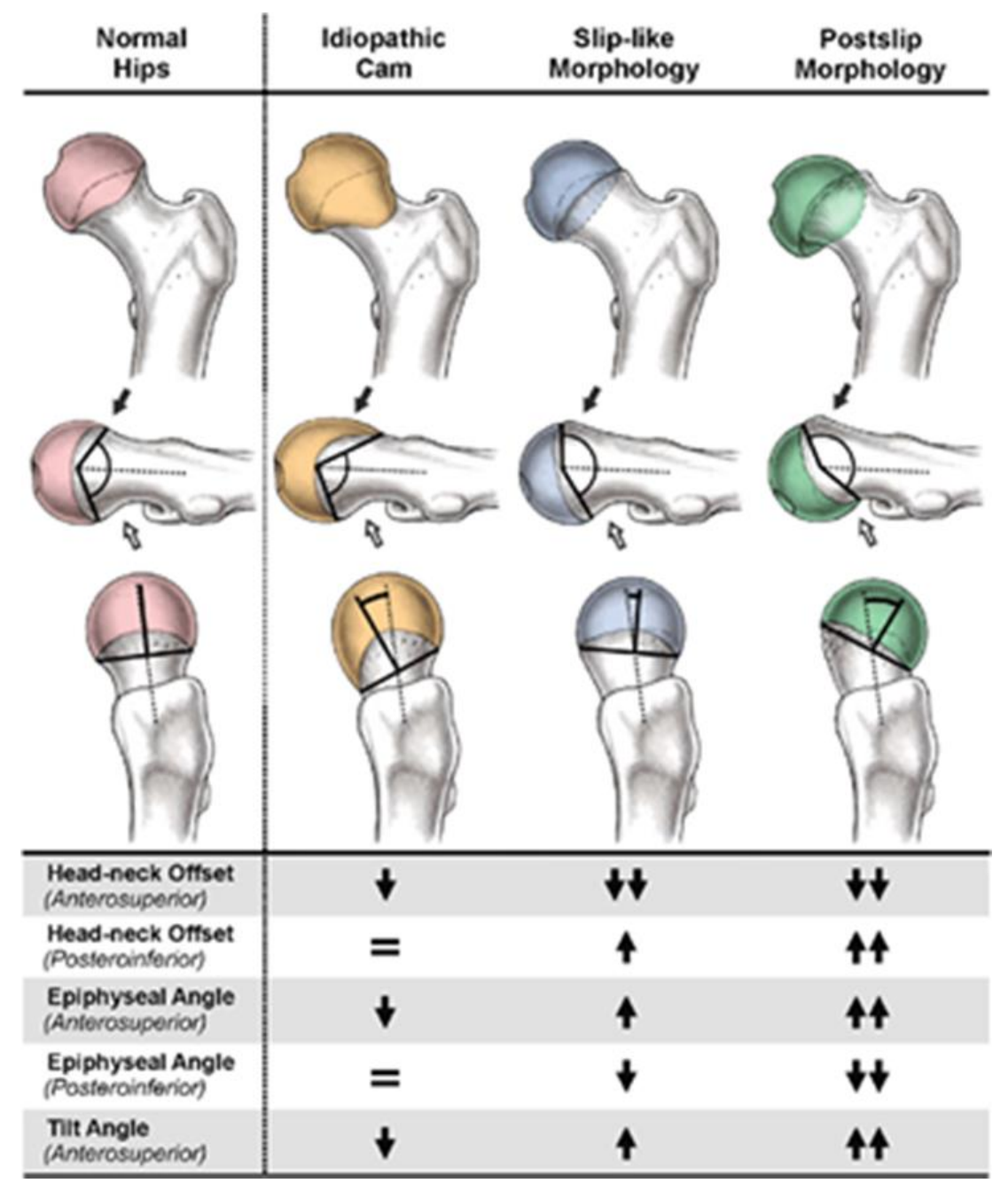
Normal Hips
Idiopathic Cam
Slip-like Morphology
Postslip Morphology
Head-neck Offset (Anterosuperior) ↓ ↓↓ ↓↓
Head-neck Offset (Posteroinferior) = ↑ ↑↑
Epiphyseal Angle (Anterosuperior) ↓ ↑ ↑↑
Epiphyseal Angle (Posteroinferior) = ↓ ↓↓
Tilt Angle (Anterosuperior) ↓ ↑ ↑↑

Results

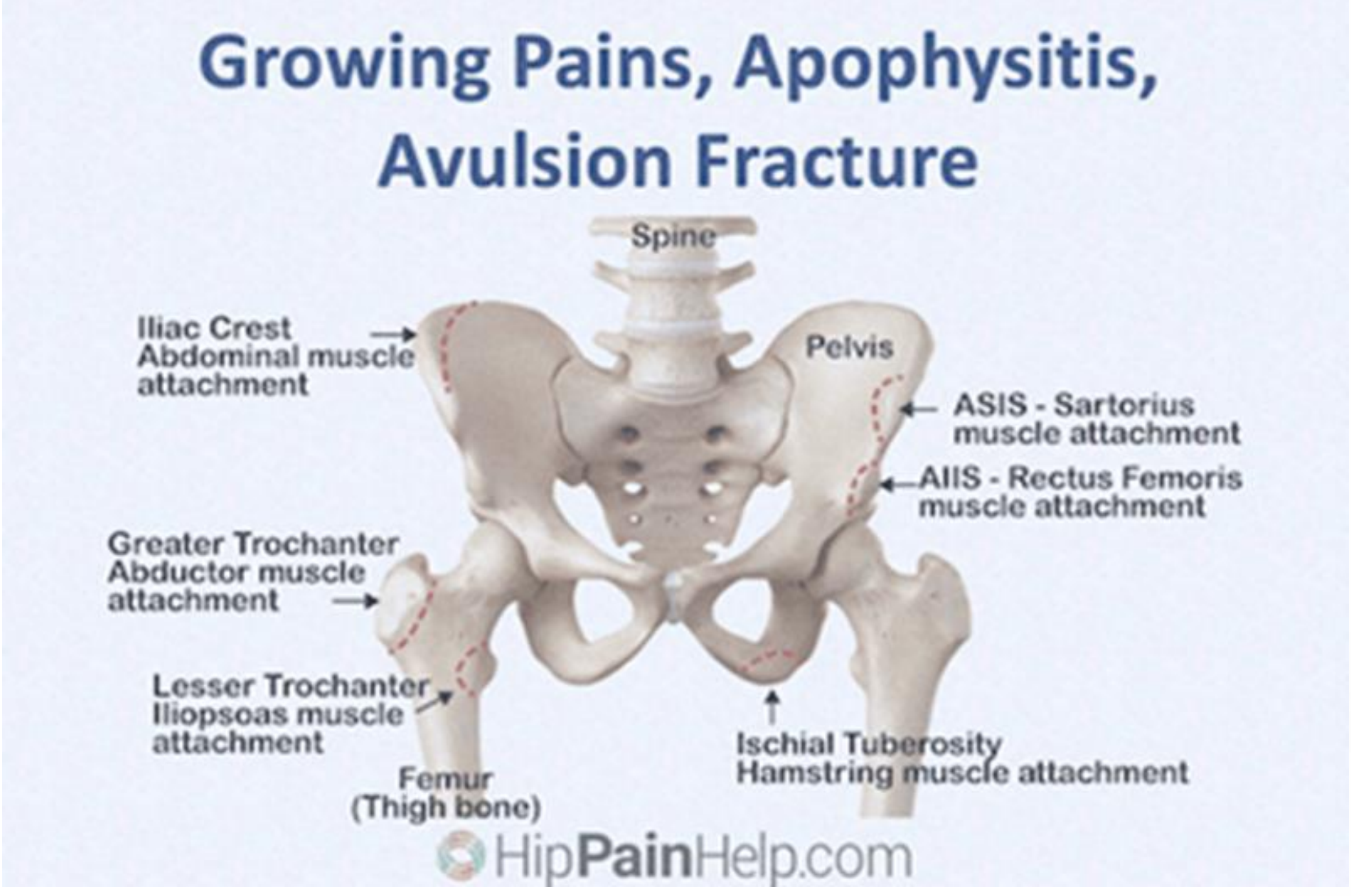
Growing Pains, Apophysitis, Avulsion Fracture
Spine
Pelvis
Iliac Crest Abdominal muscle attachment
ASIS - Sartorius muscle attachment
AIIS - Rectus Femoris muscle attachment
Greater Trochanter Abductor muscle attachment
Lesser Trochanter Iliopsoas muscle attachment
Ischial Tuberosity Hamstring muscle attachment
Femur (Thigh bone)
HipPainHelp.com

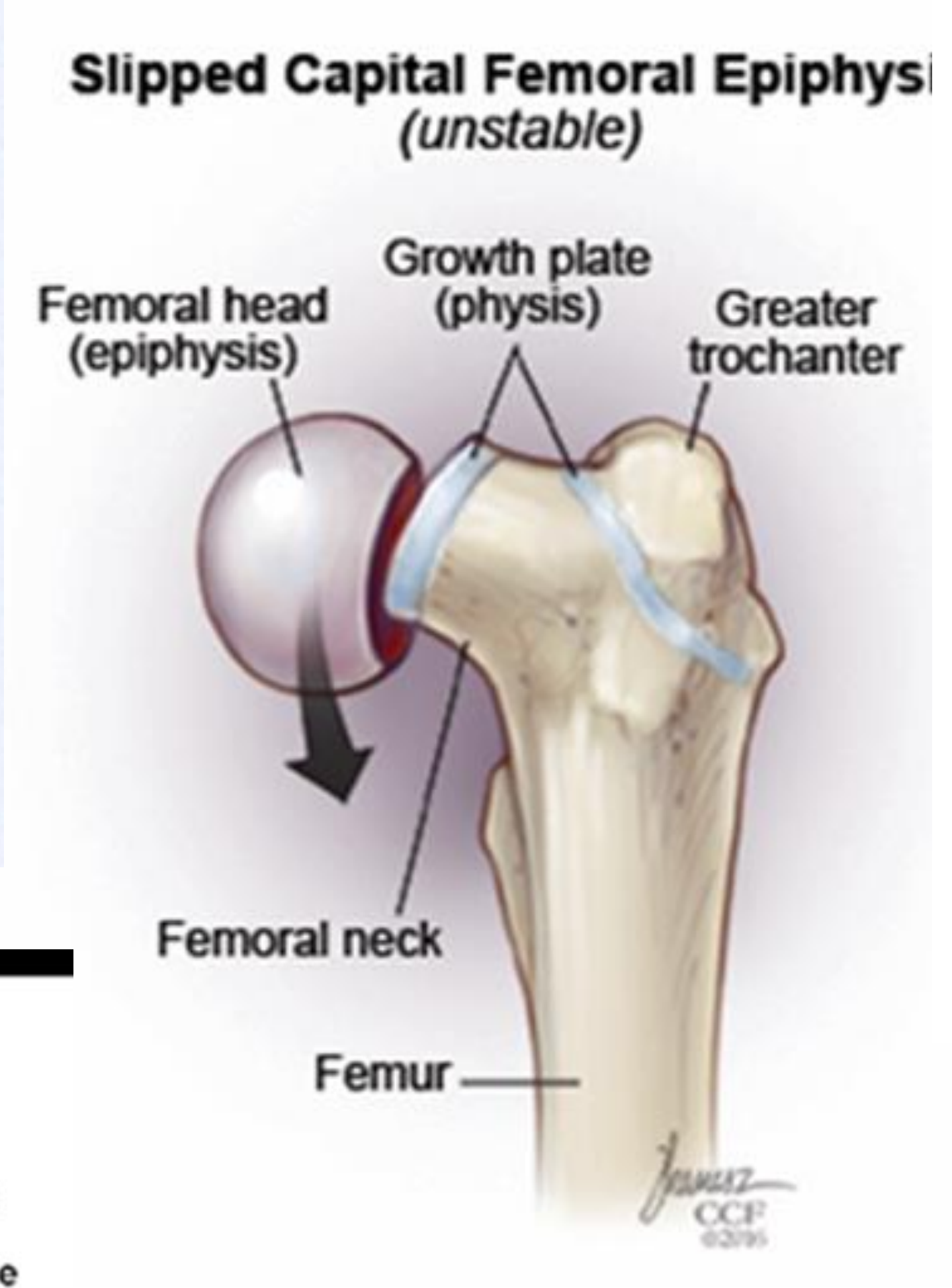
Slipped Capital Femoral Epiphysi
(unstable)
Femoral head (epiphysis)
Growth plate (physis)
Greater trochanter
Femoral neck
Femur
CCF ©2016

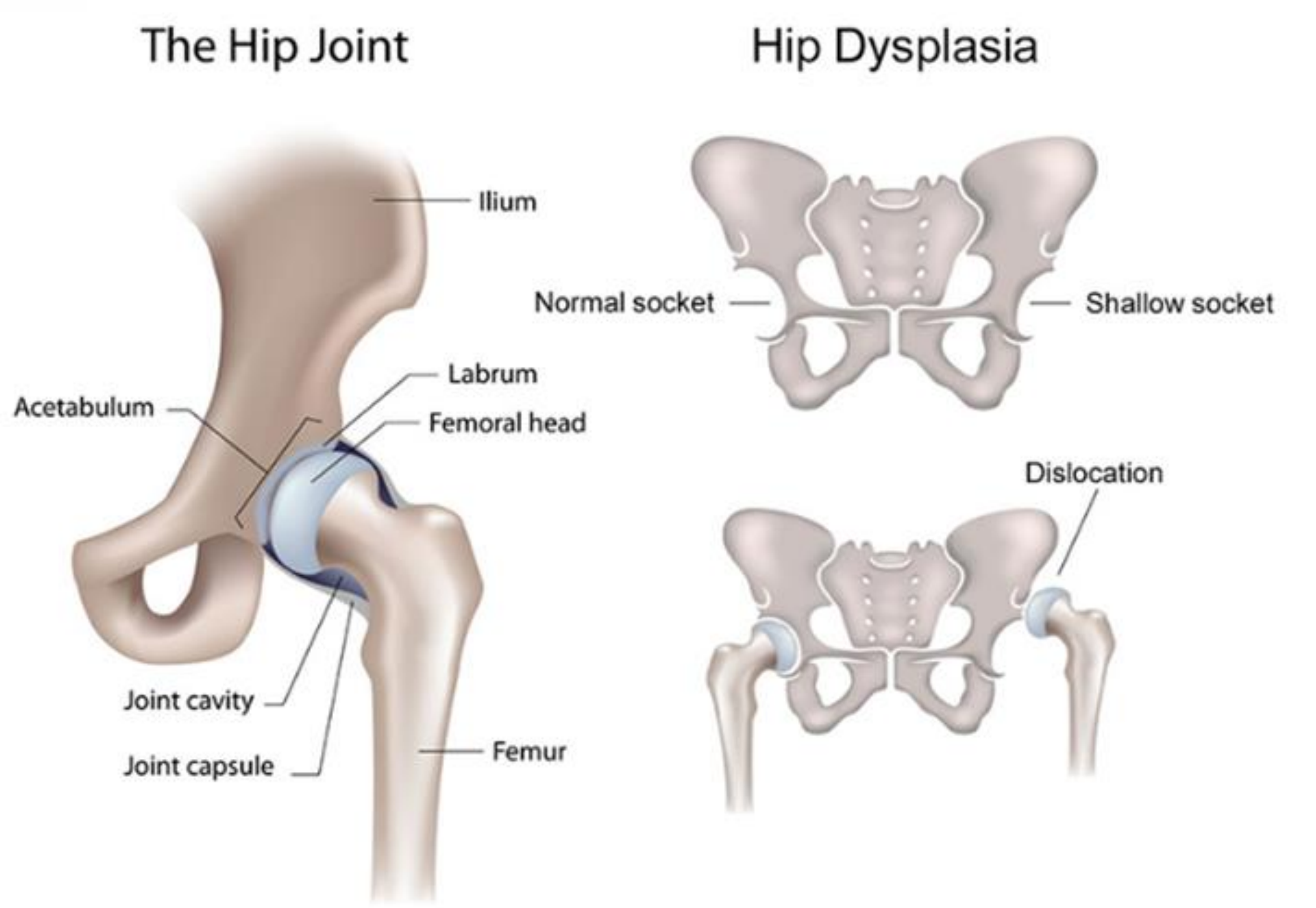
The Hip Joint
Ilium
Acetabulum
Labrum
Femoral head
Joint cavity
Joint capsule
Femur
Hip Dysplasia
Normal socket
Shallow socket
Dislocation

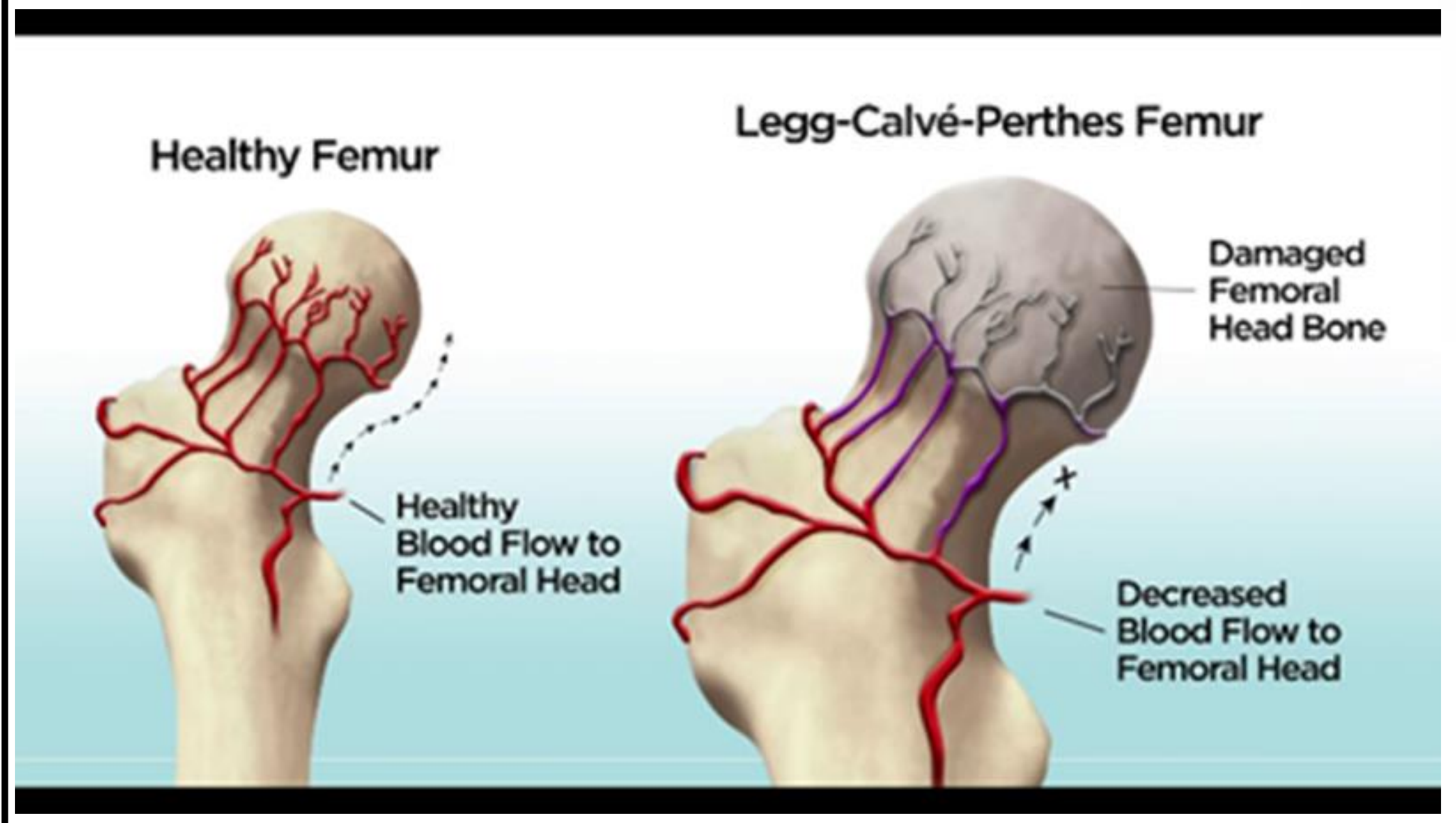
Healthy Femur
Healthy Blood Flow to Femoral Head
Legg-Calvé-Perthes Femur
Damaged Femoral Head Bone
Decreased Blood Flow to Femoral Head

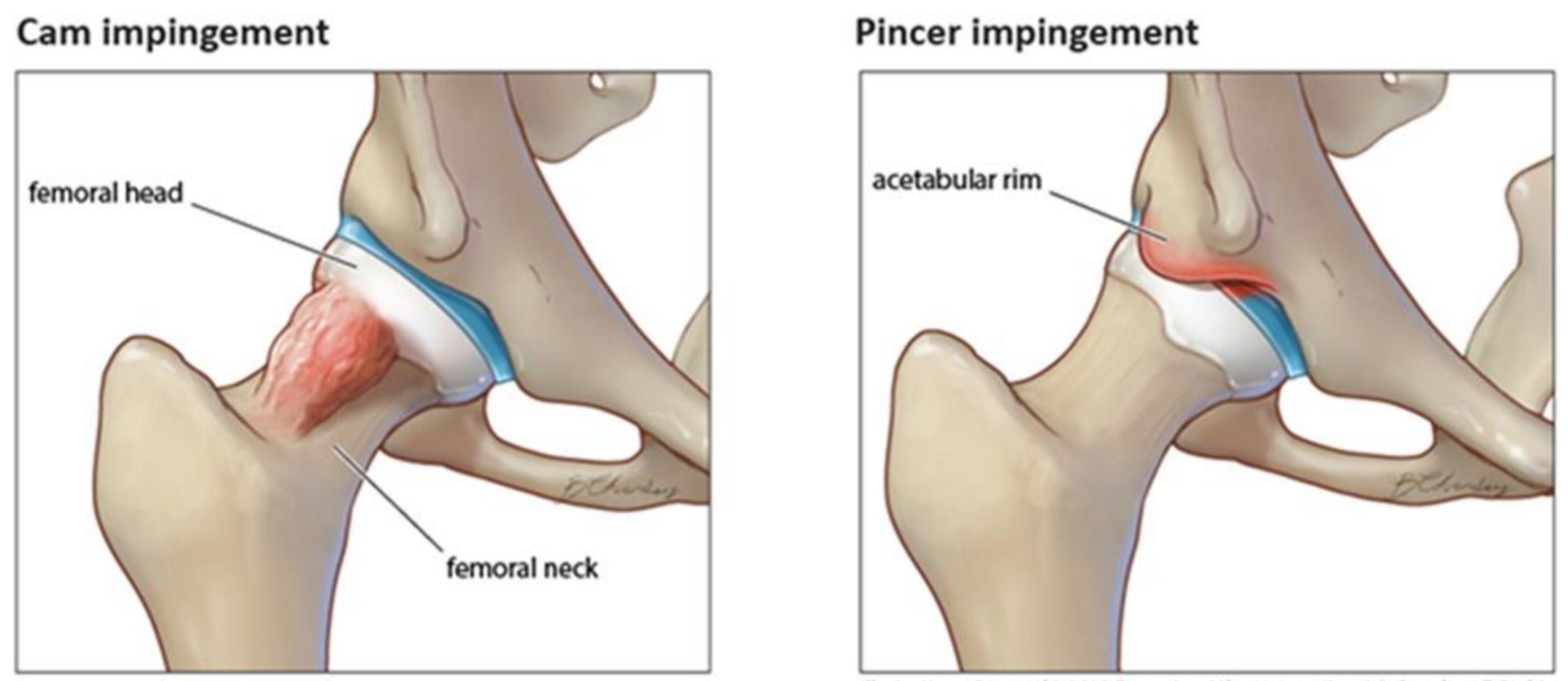
Cam impingement
femoral head
femoral neck
Pincer impingement
acetabular rim

Illustrations Copyright 2016 Regents of the University of Colorado. All Rights Reserved. Created by Berrien Chidsey, models created by Nathan Billington.

- No statistically significant differences between the alpha angle on plain radiograph, MRI, or CT ($p<0.48$).
- No statistically significant differences in alpha angle between genders on plain radiograph ($p<0.53$), MRI ($p<0.93$), or CT ($p<0.17$) for those *diagnosed with FAI.*
- When comparing open versus closed physes, open physes had significantly higher alpha angles on plain radiograph ($p<0.03$) and CT ($p<0.01$), not MRI ($p<0.11$).

Imaging Modality	Open Physes	Closed Physes	P-value
X-ray	57.7°	43.8°	0.03
MRI	57.7°	44.6°	0.11
CT	57.5°	40.3°	0.01

Conclusions

- No significant differences between alpha angles for patients diagnosed with FAI.
- Differences in alpha angles were significant when comparing open and closed physes, except with MRI.
- **Data collection is not complete.**

Implications

- Although no significant difference was observed when comparing angles of patients with FAI, subjects with open versus closed physes showed significant differences, except in MRI.
- Differences in a few degrees can greatly impact treatment recommendations.
- It appears that the use of the physeal status may help dictate which imaging modality is most effective.

Disclosures/References

- No disclosures

1. De Poorter JJ, Beunder TJ, Gareb B, Oostenbroek HJ, Bessems GH, van der Lugt JC, Maathuis PG, van der Sande MA. Long-term outcomes of slipped capital femoral epiphysis treated with in situ pinning. *J Child Orthop*. 2016; 10(5):371-379.
2. Loder RT, Skopelja EN. The epidemiology and demographics of slipped capital femoral epiphysis. *ISRN Orthop*. 2011; 2011:486512.
3. Ortegren J, Bjorklund-Sand L, Engbom M, Tiderius CJ. Continued growth of the femoral neck leads to improved remodeling after in situ fixation of slipped capital femoral epiphysis. *J Pediatr Orthop*. 2016.
4. Novais EN, Millis MB. Slipped capital femoral epiphysis: Prevalence, pathogenesis, and natural history. *Clin Orthop Relat Res*. 2012; 470:3432-3238.
5. Joseph B, Mulpuri K, Varghese G. Perthes' disease in the adolescent. *J Bone Joint Surg Br.* 2001; 83(5):715-720.
6. Shah H. Perthes disease: Evaluation and management. *Orthop Clin North Am*. 2014; 45(1):87-97.
7. Larson AN, Sucato DJ, Herring JA, Adolfsen SE, Kelly DM, Martus JE, Lovejoy JF, Browne R, DeLaRocha A. A prospective multicenter study of Legg-Calvé-Perthes disease: Functional and radiographic outcomes of nonoperative treatment at a mean follow-up of twenty years. *J Bone Joint Surg Am*. 2012; 94(7):584-592.
8. Kim SS, Lee CW, Kim HJ, Kim HH, Wang L. Treatment of late-onset Legg-Calvé-Perthes disease by arthrodiastasis. *Clin Orthop Surg*. 2016; 8(4):452-457.
9. Kotlarsky P, Haber R, Bialik V, Eidelman M. Developmental dysplasia of the hip: What has changed in the last 20 years? *World J Orthop*. 2015; 6(11):886-901.
10. Lee CB, Mata-Fink A, Millis MB, Kim YJ. Demographic differences in adolescent-diagnosed and adult-diagnosed acetabular dysplasia compared with infantile developmental dysplasia of the hip. *J Pediatr Orthop*. 2013; 33(2):107-111.
11. Huang S, Zhao D, Yang L. New approach to the treatment of adolescent hip dysplasia. *Med Hypotheses*. 2013; 81(1):122-124.
12. Gala L, Clohisy JC, Beaulé PE. Hip dysplasia in the young adult. *J Bone Joint Surg Am*. 2016; 98(1):63-73.
13. Ali E, Khanduja V. Adolescent avulsion injuries of the pelvis: A case study and review of the literature. *Orthop Nurs*. 2015; 34(1):21-26.
14. Anderson K, Strickland SM, Warren R. Hip and groin injuries in athletes. *Am J Sports Med*. 2001; 29(4):521-533.
15. Matsuda DK, Calipusan CP. Adolescent femoroacetabular impingement from malunion of the anteroinferior iliac spine apophysis treated with arthroscopic spinoplasty. *Orthopedics*. 2012; 35(3):e460-463.
16. Amar E, Warschawski Y, Sharfman ZT, Martin HD, Safran MR, Rath E. Pathological findings in patients with low anterior inferior iliac spine impingement. *Surg Radiol Anat.* 2016; 38(5):569-575.
17. Pan HL, Kawanabe K, Akiyama H, Goto K, Onishi E, Nakamura T. Operative treatment of hip impingement caused by hypertrophy of the anterior inferior iliac spine. *J Bone Joint Surg Br*. 2008; 90(5):677-679.
18. Ganz R, Parvizi J, Beck M, Leunig M, Notzli H, Siebenrock KA. Femoroacetabular impingement: A cause for osteoarthritis of the hip. *Clin Orthop Relat Res*. 2003; 417:112-120.
19. Nepple JJ, Vigdorchik JM, Clohisy JC. What is the association between sports participation and the development of proximal femoral cam deformity? A systematic review and meta-analysis. *Am J Sports Med*. 2015; 43(11):2833-2840.
20. Brunner R, Maffiuletti NA, Casartelli NC, Bizzini M, Sutter R, Pfirrmann CW, Leunig M. Prevalence and functional consequences of femoroacetabular impingement in young male ice hockey players. *Am J Sports Med*. 2016; 44(1):46-53.
21. Audenaert EA, Peeters I, Vigeron L, Baelde N, Pattyn C. Hip morphological characteristics and range of internal rotation in femoroacetabular impingement. *Am J Sports Med*. 2012; 40:1329-1336.
22. Byrd, JWT. Femoroacetabular impingement in athletes: Current concepts. *Am J Sports Med*. 2014; 42(3):737-751.
23. Ng KCG, Lamontagne M, Adamczyk AP, Rahkra KS, Beaule PE. Patient-specific anatomical and functional parameters provide new insights into the pathomechanism of cam FAI. *Clin Orthop Relat Res.* 2015; 473:1289-1296.
24. Sutter, Reto, et al. "How Useful Is the Alpha Angle for Discriminating between Symptomatic Patients with CAM-Type Femoroacetabular Impingement and Asymptomatic Volunteers?" RSNA, 1 Aug. 2012, https://pubs.rsna.org/doi/10.1148/radiol.12112479.
25. "What Does the Alpha Angle Suggest in This Hip?" Edited by Stephen Pomeranz, Proscan Imaging, 6 Aug. 2020, https://proscan.com/proscan-case-review/msk/alpha-angle-suggest-hip/.