

Ileal Ureter Replacement for Complex Ureteral Reconstruction Has a High Success Rate at 3 Year Follow Up

Bryn Launer MD¹, David Koslov MD, Kirk Redger MD, Anessa Sax-Bolder* BA, Ty Higuchi MD PhD, Brian J Flynn MD

¹, University of Colorado School of Medicine, Aurora, CO.

², Division of Urology, University of Colorado Denver School of Medicine, Aurora, Colorado

PURPOSE

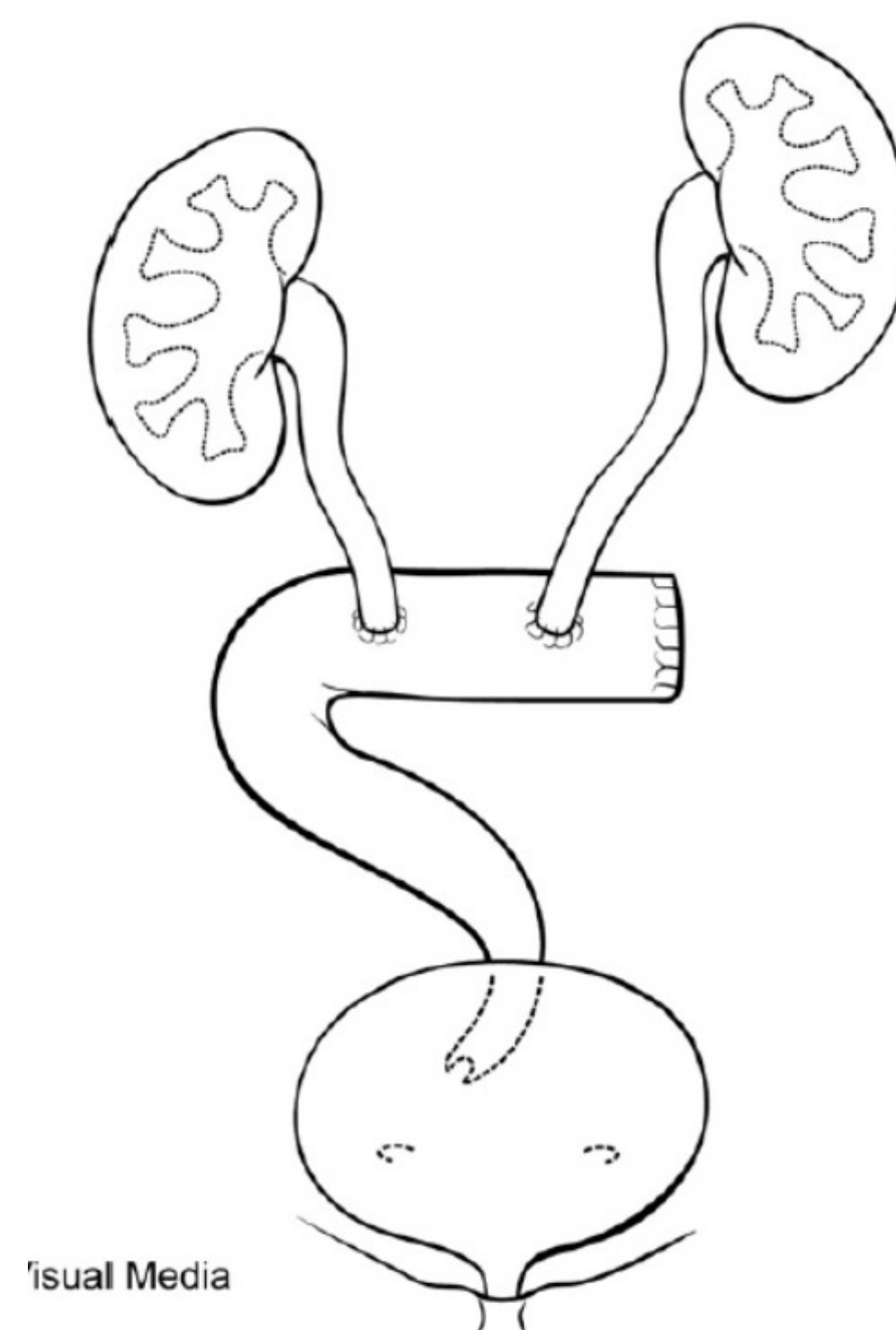
- Complex or lengthy ureteral strictures may require ileal ureter interposition, which remains an important option for ureteral reconstruction.
- Reported long term success rate is 75-85%.
- We report on our 16 year institutional experience with ileal ureter interposition.

Author, Year	Description	% Bilateral	% Complications	Average fu months	% Success Rate	Definition of Failure
Monn et al., 2018	Radiation cases	18.2	29.8	39.2	102/104	98% Anastomotic stricture
Stein et al., 2009	Laparoscopic v. Open	14.3	35.7	30	14/14	100% Anastomotic stricture
Chung et al., 2006	Long-term fu	3.5	28.6	72.4	54/56	96% Anastomotic stricture
Matlaga et al., 2003	Contemporary series	11.1	16.6	18.6	18/18	100%
Shokeir et al., 1995	Modified ileal ureter	0	--unk	69	44/50	88% Urinary obstruction
Boxer et al., 1979	UCLA Series	0	--unk	--unk	72/89	81% Unsuccessful operation

Table 1. Contemporary Series of Ileal Ureteral Interposition

MATERIALS AND METHODS

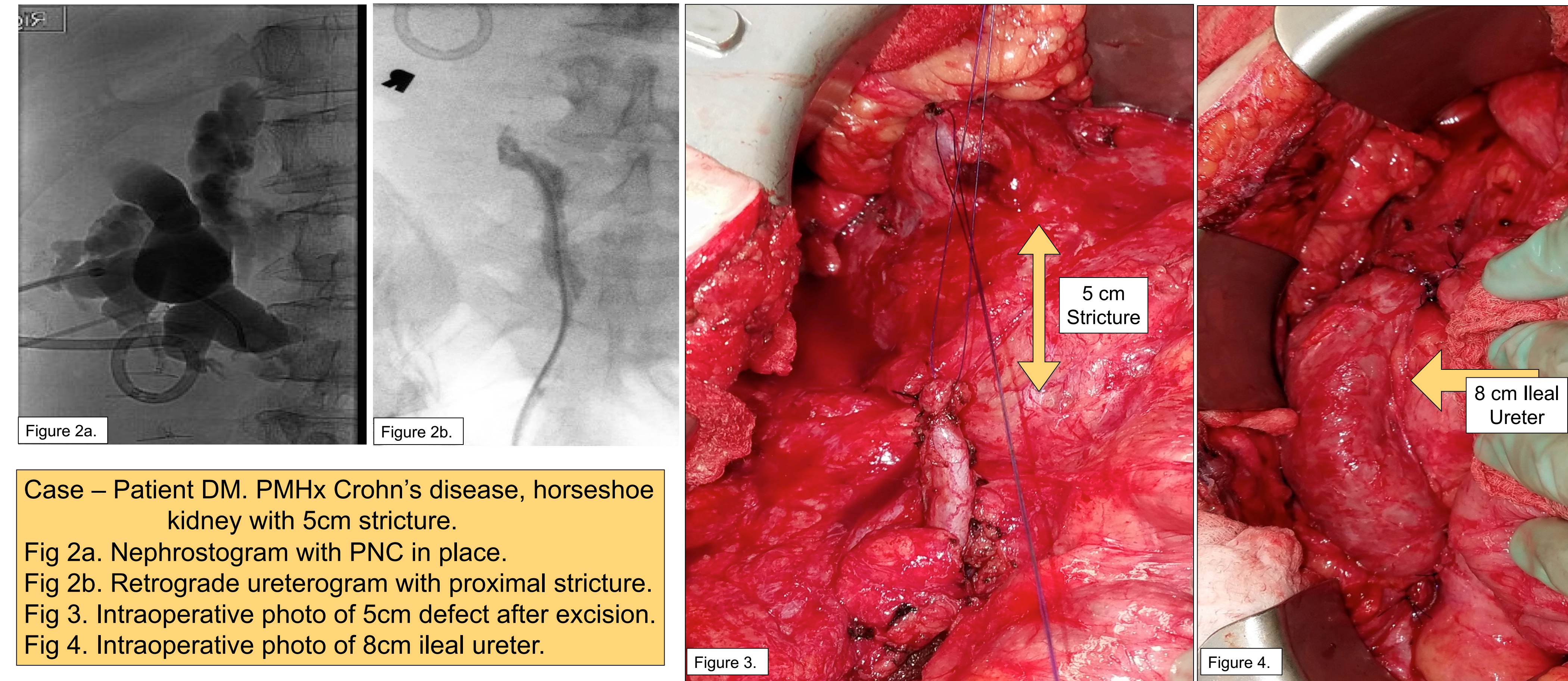
- Retrospective review of a single institution's ureteral reconstruction database was performed (2003-2019).
- Three urologic surgeons performed all surgeries.
- Unilateral replacements utilized ureteral interposition when possible. Bilateral ileal ureters were performed using the "reverse 7" approach.
- Preoperative patient demographics, ureteral stricture characteristics, intraoperative variables, complications, and secondary procedures were recorded.
- Success rate was defined as no need for further intervention.



Reverse-Seven Configuration

Figure 1. Armatys and Bihrl: J Urol 2009

RESULTS



Case – Patient DM. PMHx Crohn's disease, horseshoe kidney with 5cm stricture.
Fig 2a. Nephrostogram with PNC in place.
Fig 2b. Retrograde ureterogram with proximal stricture.
Fig 3. Intraoperative photo of 5cm defect after excision.
Fig 4. Intraoperative photo of 8cm ileal ureter.

- Between 2003 and 2019, 188 ureteral reconstructions were performed, of which 46 required ileal ureter interposition (10 bilateral).
- Average age = 53 years, 44% male, 96% Caucasian, 11% Hispanic/Latino.
- Stricture etiology: iatrogenic causes (n=24, 52%), radiation (n=12; 26%), vascular disease (n=3; 7%), idiopathic retroperitoneal fibrosis (n=3; 7%), and other causes including congenital and trauma (n=4; 9%).
- Half (n=23) received prior intervention, all required prior stent or PCN.
- 23 patients (50%) had any complication (Clavien Dindo 1–5)
- 11 (24%) patients had a major (Clavien Dindo 3a or greater) complication
- At avg. of 3.3 year follow up 8 (17%) patients required additional open procedures
- Of those 8:
- 3 ultimately required nephrectomy due to persistent pain or pyelonephritis
- 5 underwent successful revision of the ileal ureter

Outcomes	Radiated (n=19)	Non-Radiated (n=27)	Total (n=46)
	Mean	Mean	Mean
Stricture length (cm)	11.22	7.77	9.13
Length of operation (min)	452	372	412
Estimated Blood Loss (mL)	561	255	417
Length of Stay (days)	13.5	7.52	10
Successful outcome	89% (17)	78% (21)	83% (38)

Table 2. Peri-operative and long-term outcomes after ileal ureter interposition

CONCLUSIONS

- In our long-term follow up of over 3 years, ileal ureter interposition is a successful option for complex ureteral strictures in properly selected patients.
- Utilization of the "Care Everywhere" function in Epic allows for acquisition of additional follow-up data from patients followed out-of-state.
- Limitations of this series include biases associated with retrospective conclusions drawn from a single-center institution. Additionally, the length of follow up varies due to the nature of referrals to a tertiary academic center.
- Alternatives to ileal ureteral interposition for complex ureteral strictures include autotransplantation and lower ureteral reconstruction.
- In this single-institution retrospective cohort, long-term outcomes at 4 years are comparable to the existing literature, with an 83% success rate in which no further open procedures are required.

Selected References

- Armatys, S. A., Mellon, M. J., Beck, S. D., Koch, M. O., Foster, R. S., & Bihrl, R. (2009). Use of ileum as ureteral replacement in urological reconstruction. The Journal of urology, 181(1), 177-181.
- Boxer, R. J., Fritzsche, P., Skinner, D. G., Kaufman, J. J., Belt, E., Smith, R. B., & Goodwin, W. E. (1979). Replacement of the ureter by small intestine: clinical application and results of the ileal ureter in 89 patients. The Journal of urology, 121(6), 728-731.
- Chung, B. I., Hamawy, K. J., Zinman, L. N., & Libertino, J. A. (2006). The use of bowel for ureteral replacement for complex ureteral reconstruction: long-term results. The Journal of urology, 175(1), 179-183.
- Matlaga, B. R., Shah, O. D., Hart, L. J., & Assimos, D. G. (2003). Ileal ureter substitution: a contemporary series. Urology, 62(6), 998-1001.
- Monn, M. F., Roth, J. D., Bihrl, R., & Mellon, M. J. (2018). Long term outcomes in the use of ileal ureter for radiation-induced ureteral strictures. International urology and nephrology, 50(8), 1375-1380.
- Shokeir, A. A., & Ghoneim, M. A. (1995). Further experience with the modified ileal ureter. The Journal of urology, 154(1), 45-48.
- Stein, R. J., Turna, B., Patel, N. S., Weight, C. J., Nguyen, M. M., Shah, G., . . . Desai, M. M. (2009). Laparoscopic assisted ileal ureter: technique, outcomes and comparison to the open procedure. The Journal of urology, 182(3), 1032-1039.

Acknowledgements & Disclosures

Financial Disclosures: None

Acknowledgements: The authors would like to thank the house staff at UCH for their efforts in contributing to this study.

For questions or the full EndNote bibliography:
Anessa.sax-bolder@cuanschutz.edu