

Sharp Recanalization with the Upstream GoBack Catheter for Chronic Occlusive Ilio-Caval Thrombosis

Roxana Tabrizi, MS4¹, Limael E. Rodriguez, MD², Rafael D. Malgor, MD², Max Wohlauser, MD², and Donald L. Jacobs, MD²

1. University of Colorado School of Medicine

2. University of Colorado Hospital, Department of Vascular Surgery

Introduction

Percutaneous recanalization with or without stenting has replaced bypass surgery as the primary treatment option for obstructed iliac veins¹⁻². When standard techniques of recanalization fail, evidence suggests there is a clinical benefit of further attempts at recanalization utilizing alternative methods³. We present a case of inferior vena cava (IVC) and bilateral iliac vein occlusions that were successfully recanalized using the recently approved Upstream GoBack Crossing Catheter.

Case Report

Woman in her 40's with Protein C deficiency and heterozygous Factor V Leiden gene mutation. Had a prophylactically placed Denali IVC filter seven years ago prior to elective back surgery, with failed attempt at filter retrieval and several acute iliofemoral deep vein thromboses requiring pharmaco-mechanical thrombectomy. She presented with chronic abdominal and back pain, worse with bearing down. She also had painful varicose veins in her groin and abdominal wall with bilateral leg swelling. An ascending venogram in February 2020 showed bilateral iliac vein occlusions with a thrombosed IVC filter (Figure 1A). She was consented for a second attempt at IVC filter retrieval with possible IVC and iliac vein recanalization.

Acknowledgments

University of Colorado Hospital, Department of Vascular Surgery

Technical Details

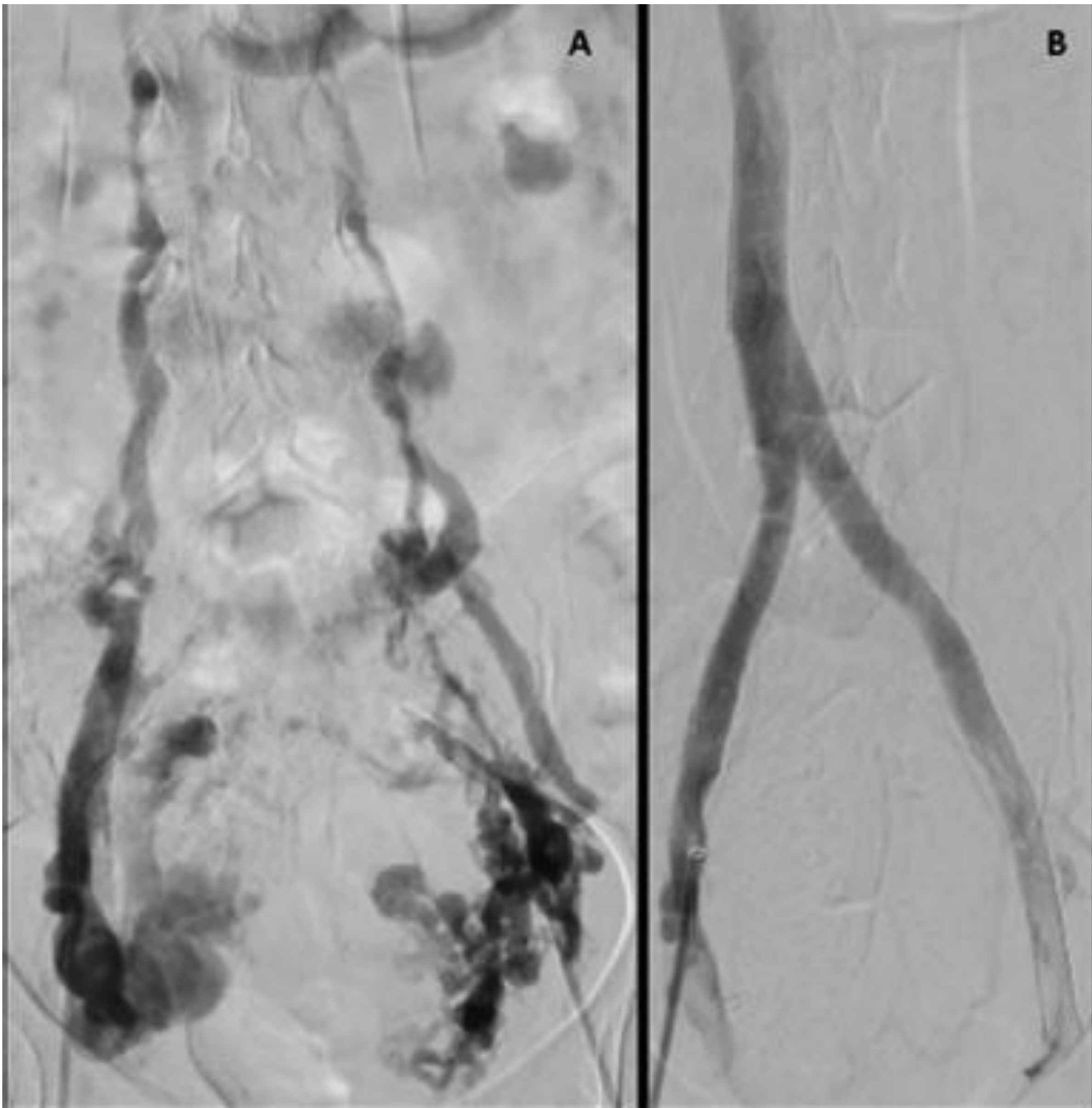


Figure 1: (A) Initial venogram showing thrombosed left internal/external iliac veins. Right external iliac is patent with a thrombosed common iliac segment. Drainage bilaterally via collaterals. (B) Completion venogram with inline flow through ilio-caval stents into the native IVC.

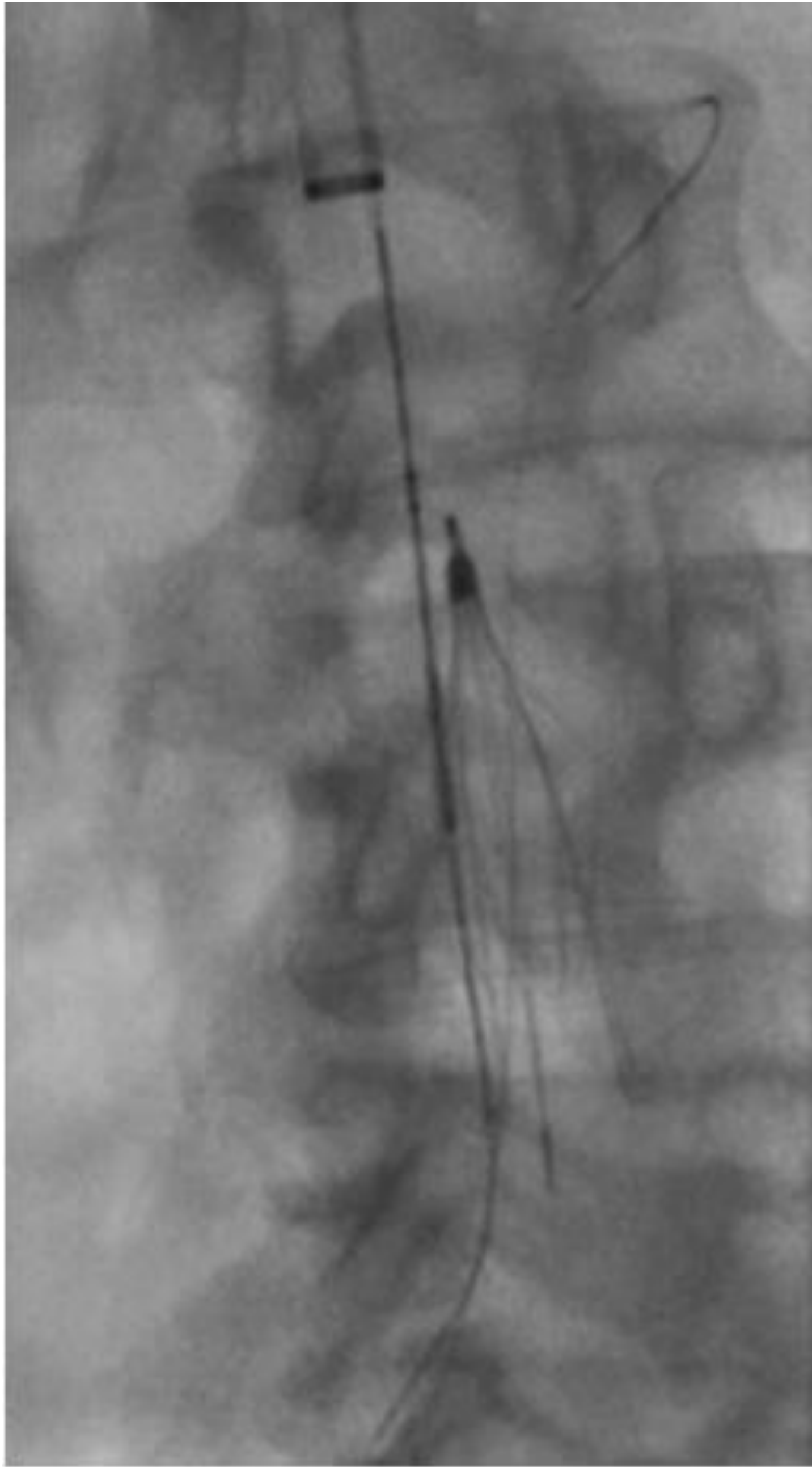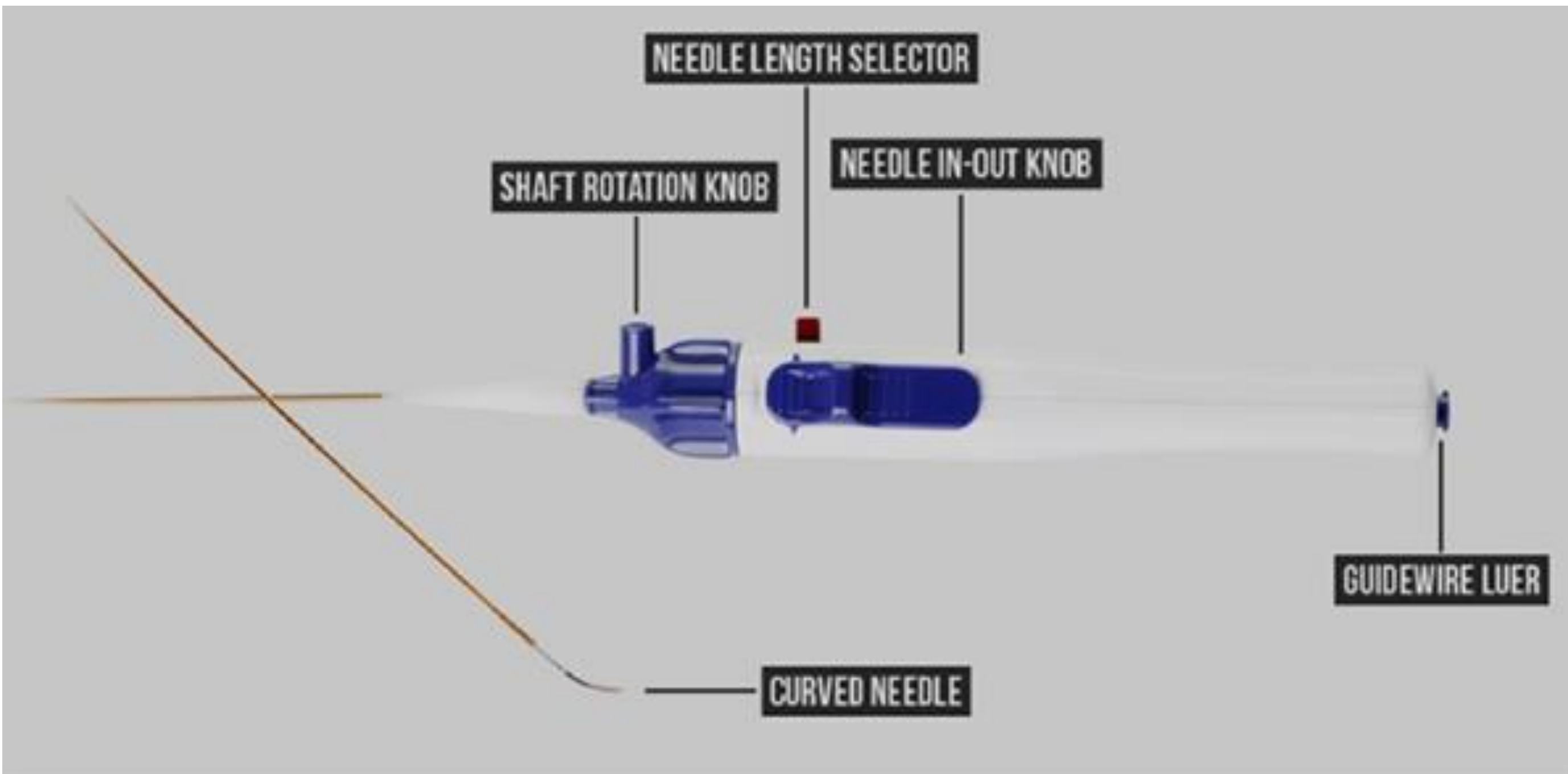


Figure 2: After unsuccessfully attempting to cross the IVC chronic total occlusion (CTO) with different wires and support catheters, a 2.9 mm Upstream GoBack Catheter was used with a Winn 200T 0.014" wire to cross the CTO.

Figure 3: The GoBack Catheter is a support catheter with a pre-curved lancet tip at its distal end and a hub at the proximal end for guidewire access. Maximum needle tip protrusion is 8mm with an angle of 35 degrees at this extension but can be adjusted to protrude to shorter distances with less or no curve. The needle has a radio-opaque marker that demonstrates the needle tip's curvature while retracted. The needle can be deployed in a stepped fashion, initially with just sharp tip exposure and then with maximum curvature in the fully advanced position, allowing for sharp dissection in a directional manner.

Discussion and Conclusion

Initial attempts at crossing CTOs of the ilio-caval venous segments traditionally involve a combination of hydrophilic guidewires and support catheter system. However, studies have shown up to 11% of failed first attempts at recanalization with standard techniques and up to 13% of cases requiring more advanced techniques for subsequent attempts⁴⁻⁵. When blunt recanalization is unsuccessful, sharp recanalization is a safe and efficacious alternative⁶. After several attempts utilizing standard catheter and wire recanalization techniques, we effectively crossed chronic ilio-caval obstructions using the Upstream GoBack Crossing 2.9 Fr support catheter and 0.014" wire (Figures 2 and 3). While injury to adjacent vascular structures, perforation, and retroperitoneal hematoma have been described with other sharp modalities, we did not have any complications. At 3 months follow up, the patient had widely patent IVC and bilateral iliac vein stents, near resolution of her symptoms, and significantly improved quality of life (Figure 1B).

References

1. Ito N, Isfort P, Penzkofer T, et al. Sharp recanalization for chronic left iliac vein occlusion. *Cardiovasc Intervent Radiol*. 2012;35:938–941.
2. Murphy EH, Johns B, Varney E, et al. Endovascular management of chronic total occlusions of the inferior vena cava and iliac veins. *J Vasc Surg Venous Lymphat Disord*. 2017;5:47–59.
3. Raju S, McAllister S, Neglen P. Recanalization of totally occluded iliac and adjacent venous segments. *J Vasc Surg*. 2002;36:903–911.
4. Raju S, Neglén P. Percutaneous recanalization of total occlusions of the iliac vein. *J Vasc Surg*. 2009;50:360–368.
5. Fatima J, AlGaby A, Bena J, et al. Technical considerations, outcomes, and durability of inferior vena cava stenting. *J Vasc Surg Venous Lymphat Disord*. 2015;3:380–388.
6. McDevitt JL, Srinivasa RN, Gemmete JJ, et al. Approach, technical success, complications, and stent patency of sharp recanalization for the treatment of chronic venous occlusive disease: experience in 123 patients. *Cardiovasc Intervent Radiol*. 2019;42:205–212.